The limping child

Tosan Okoro takes us through the approach and management of limp disorders in children

PHOTOS.COM

A limp is a common reason for a child to present to the doctor.[1] Because of the long list of potential diagnoses, some of which demand urgent treatment, an organised approach to evaluation is required. It is essential to understand the components of gait and the pathophysiology of specific abnormalities. Gait reflects the coordinated action of the lower extremities. The body moves forwards smoothly with economy of motion and energy. The stance phase (60% of the entire gait cycle) is the weight bearing portion.[2] It is initiated by heel contact and ends with toe lift-off from the same foot. Swing phase is initiated with toe off and ends with heel strike. Limb advancement occurs during the swing phase (40% of normal gait cycle; fig 1). During this phase the foot pronates first and then supinates. Pronation shortens the foot, which helps it to clear the ground. Pronation also minimises the energy expenditure necessary for ground clearance as the non-weight bearing limb passes the weightbearing limb.[2] Supination stabilises the bony architecture of the foot thus preparing it for heel strike, when the foot must absorb the shock of striking the ground. Table 1 shows the develop-

Table 1 Developmental stages of gait[4]

Age (months)	Developmental stage
10-12	Cruises while holding on to objects
12-14	Walks short distances and stands unaided
17-21	Walks on one foot long enough to walk up steps
30-36	Balances on one foot for more than one second
36	Develops sufficient balance to attain a normal gait pattern

Box 1: History — questions to be asked[5]

- Duration and progression of limp?
- Recent trauma and mechanism? Beware limitations of paediatric history and possibility of unintentional trauma
- Associated pain and its characteristics?
- Accompanying weakness?
- Time of day when limp is worse?
- Can the child walk or bear weight?
- Has the limp interfered with normal activities?
- Presence of systemic symptoms like fever, weight loss?
- Do not forget the medical history, BIND—birth history, immunisation history, nutritional history, and developmental history
- Also include the other essentials—drug history and allergies and family history

Box 2: Common causes[7]

1-5 years old
- Trauma
- Transient synovitis
- Osteomyelitis or septic arthritis
- Developmental dysplasia of the hip
- Juvenile rheumatoid arthritis

5-10 years old
- Trauma
- Transient synovitis
- Osteomyelitis or septic arthritis
- Legg-Calve-Perthes disease

10-15 years old
- Trauma
- Osteomyelitis or septic arthritis
- Slipped upper femoral epiphysis
- Chondromalacia
- Neoplasm

mental progression of a child's gait, which should be incorporated into the assessment.

Gait differences

The gait of a child is different from that of an adult for the first three years of life.[5] Children typically take a lot more steps per minute at a slower speed than adults to compensate for their immature balance. Toddlers tend to flex their hips, knees, and ankles more than adults in order to lower their centre of gravity and improve their balance.[5]

History

The history for a child with a limp should be detailed (see box 1). The examination of a child starts with basic observation, which depends on the age as well as the level of cooperation and discomfort. The hip is most commonly examined, but one should not fail to consider referred pain from the knee. It is best to follow the normal orthopaedic routine of look, feel, move, and special tests outlined in table 2.

The common causes of limp by age group are in box 2. If there has been unilateral limitation of all hip movements, spontaneous recovery after bed rest, and normal radiology, a retrospective diagnosis of transient synovitis of the hip is made if all three prerequisites are met. If other joints are involved, juvenile idiopathic arthritis should be considered.

Investigations

The investigations that are useful in the assessment of a limping child are given in table 3.

Treatment options

The therapeutic options depend on the diagnosis. The options are laid out in box 3 (on studentbmj.com) along with salient clinical features and investigation findings for each clinical condition.

In conclusion, a variety of causes exist for a limp in a child, but it is important to bear in mind the components of the gait cycle in order to assess this common complaint. The tried and trusted sequence of history taking, clinical examination, investigations, and management applies more than ever.

Tosan Okoro *senior house officer, neurosurgery, Walsall Manor Hospital,* **Gabriel Alo** *consultant orthopaedic surgeon, Queen Elizabeth Hospital, Birmingham*
Tosanwumi@hotmail.com

1 Flynn JM, Widmann RF. The limping child: evaluation and diagnosis. *J Am Acad Orthop Surg* 2001;9:89-98.
2 Barkin RM, Barkin AZ, Barkin SZ. The limping child. *J Emerg Med* 2000;18:331-9.
3 Beverley Hills Prosthetics Orthotics. Gait cycle. www.bhpoinc.com/prosthetics_products_and_service.htm (accessed 8 Dec 2005).
4 Thompson GH. Bone and joint disorders: evaluation of the child. In: Behrman RE, Kliegman RM, Jenson HB, eds. *Nelson textbook of paediatrics.* 17th ed. part XXXI. London: Saunders, 2004: 2252, 2274.
5 Kerrigan DC, Schaufele M, Wen MN. Gait analysis. In: Deelisa JA, Gans DM, eds. *Rehabilitation medicine: principles and practice.* 3rd ed. Philadelphia: Lippincott-Raven, 1998.
6 MacEwen GD, Dehne R. The limping child. *Pediatr Rev* 1991;12:268-74
7 Leet AI, Skaggs DL. Evaluation of the acutely limping child. *Am Fam Physician* 2000;61:1011-8.
8 Dabney KW, Lipton G. Evaluation of limp in children. *Curr Opin Pediatr* 1995;7:88-94.
9 DeAngelis NA, Busconi BD. Hip arthroscopy in the pediatric population. *Clin Orthop Relat Res* 2003;406:60-3.
10 Connolly LP, Treves ST. Assessing the limping child with skeletal scintigraphy. *J Nucl Med* 1998;39:1056-61.
11 Kermond S, Fink M, Graham K, Carlin JB, Barnett P. A randomized clinical trial: should the child with transient synovitis of the hip be treated with nonsteroidal anti-inflammatory drugs? *Ann Emerg Med* 2002;40:294-9.

Table 2 Examination of a child[7]

Examination	Points to consider
Look	For evidence of deformity, erythema, swelling, effusion, limitation of motion, asymmetry. Assess shoes for unusual wear on the soles, asymmetry, point of initial foot strike, and also assess the fit. In older children look for scoliosis, midline dimples, and hairy patches, which could indicate spinal pathology. Assess gait with the child barefoot. Any discomfort as the child bends down
Feel and move	Measure true leg length from the anterior superior iliac spines to medial malleoli. Assess thigh or calf circumference if asymmetry suggests atrophy. Feel for warmth, fluctuance, palpable masses, stiffness. Assess range of movement, laxity, stiffness with guarding, pain, discomfort, and fluidity
Special tests	Neurological assessment of the lower limbs is essential.[6] The range of spinal motion (in flexion and extension) should be tested and recorded. Prone internal rotation of the hip is the most sensitive test for intra-articular pathology. With the child prone and the pelvis kept flat on the table, the knees are flexed and the ankles left to fall away from the body. Any inflammation in the hip manifests as decreased internal rotation of the hip. The FABER *test* (hip **f**lexion, **ab**duction and **e**xternal **r**otation) is performed by placing the ipsilateral ankle on the contralateral knee in the supine patient and then providing gentle downward pressure on the knee. This test is positive if it causes pain in the sacroiliac joint which may be involved in adolescents in infectious and inflammatory conditions. The Galeazzi test is performed by putting the child in a supine position and bringing the ankles to the buttocks with the hips and knees flexed. The test is positive when the knees are at different heights, suggesting developmental dysplasia or a leg length discrepancy

Table 3 Investigations for assessing limp in children[7-10]

Investigation	Aids to diagnosis
Full blood count	Differential white cell count
Erythrocyte sedimentation rate	More specific in indicating the presence of infection than C reactive protein assay but not as sensitive
C reactive protein assay	Most sensitive early test for musculoskeletal infections; abnormally high values rapidly return to normal after effective treatment
Joint aspiration	If effusion is present. Requires cell count and differential, Gram's stain, and culture and sensitivity
Blood cultures	For causative organism in septic arthritis, and osteomyelitis; it may need to be repeated at peaks of temperatures
Imaging	Plain x ray of hip as part of initial study. Yield is low if specific findings are not noted on physical examination. X ray of the limb above and below the affected area may also be useful. A bone scan is sensitive but not highly specific; it defines areas of increased or decreased metabolic activity caused by neoplasm, infection, or avascular disease. Ultrasound is useful for assessing for joint effusion or abscess. Computed tomography defines bone and soft tissues anatomically. Magnetic resonance imaging is most effective in evaluating neurological disorders such as disciitis and spinal tumours
Surgical	Hip arthroscopy is also an option; it is significantly less invasive than arthrotomy and avoids dislocation of the femoral head and the corresponding risk of osteonecrosis.

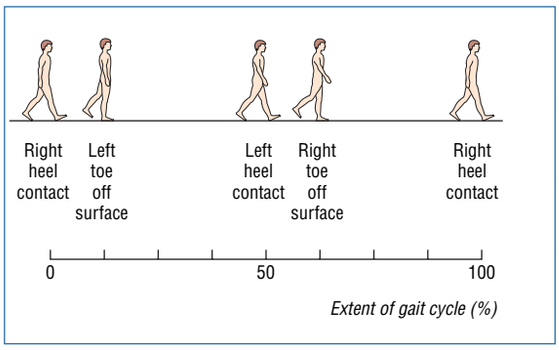

Fig 1 The gait cycle[3]

Box three for this article is on studentbmj.com